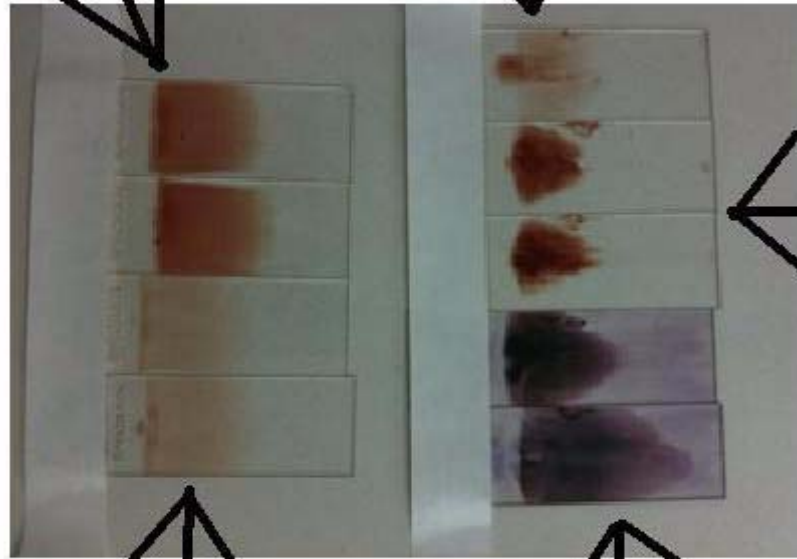


Ehrlichia Smears

Example of two well made buffy coat slides. Notice how they are lighter in appearance than the two peripheral smears to the right.



Example of two well made peripheral smears.

Example of two poorly made buffy coat slides after staining. See the feather edge on both of these slides are like a tongue. A peripheral slide does not have a smooth feather edge and is difficult to read.

Example of a buffy coat smear that is thinner in appearance, too short to read.

Example of buffy coat smears that are too short and too thick.